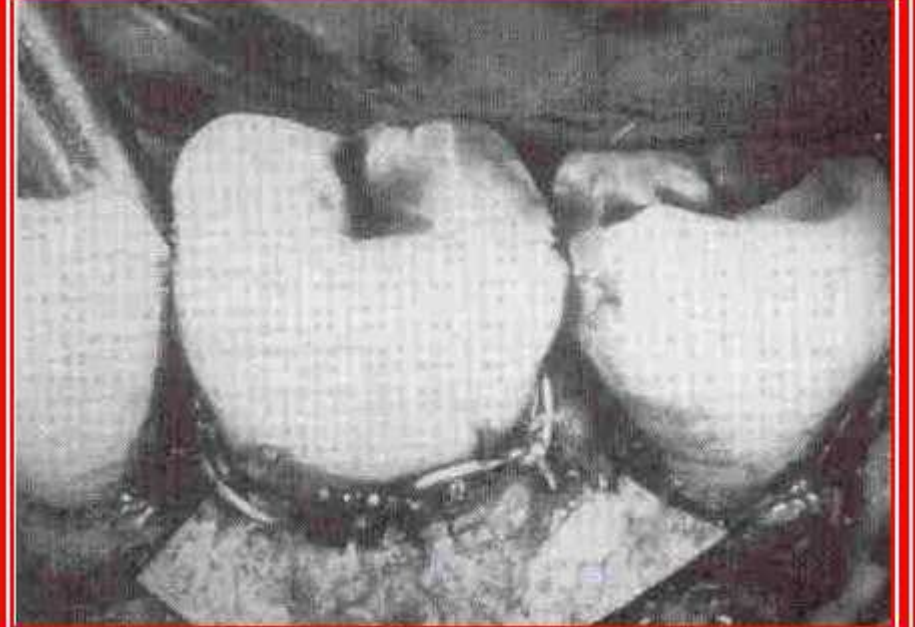
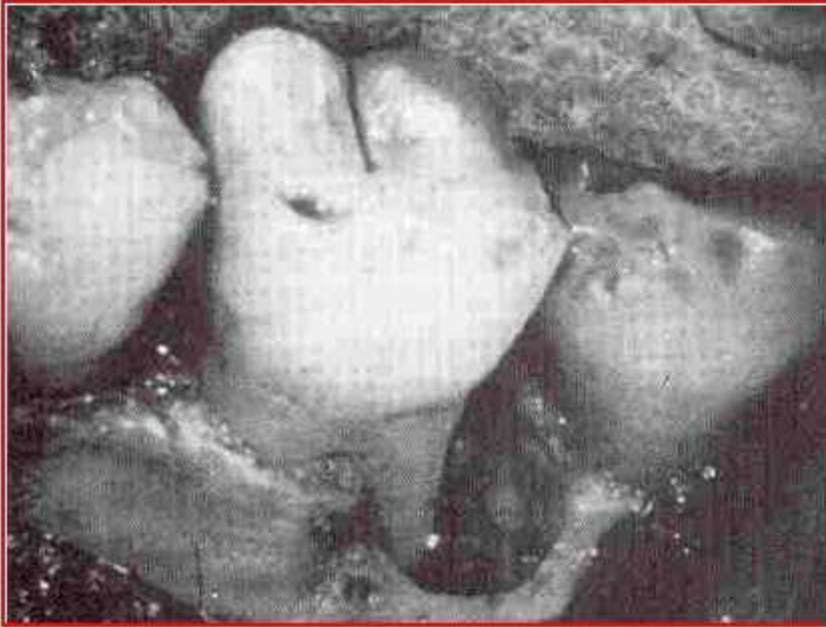
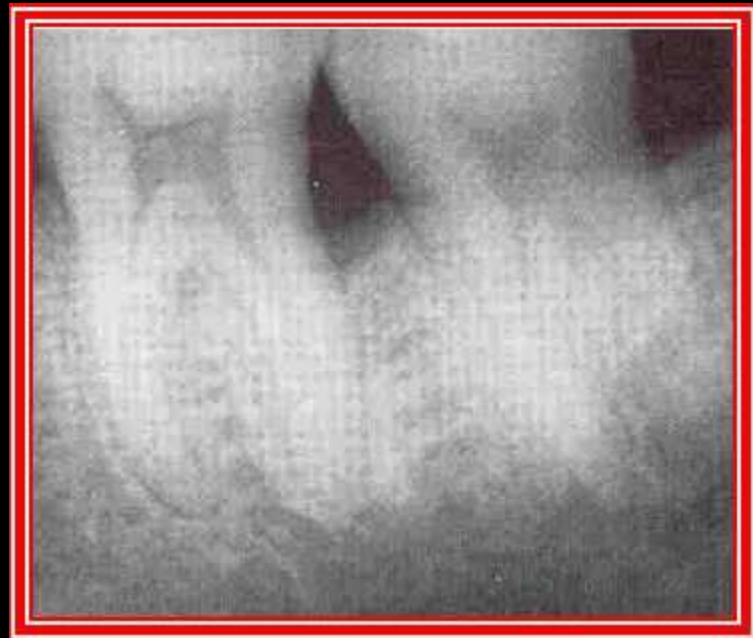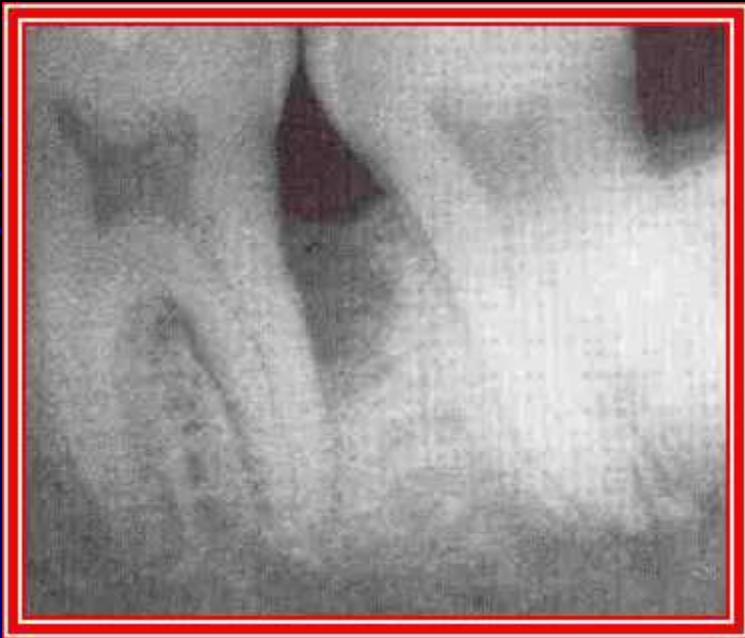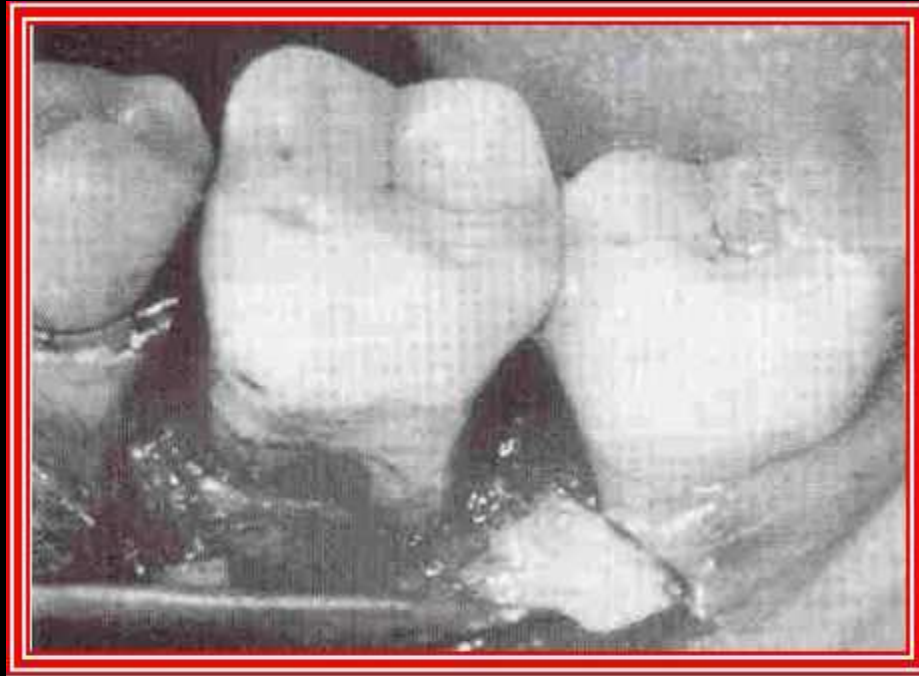


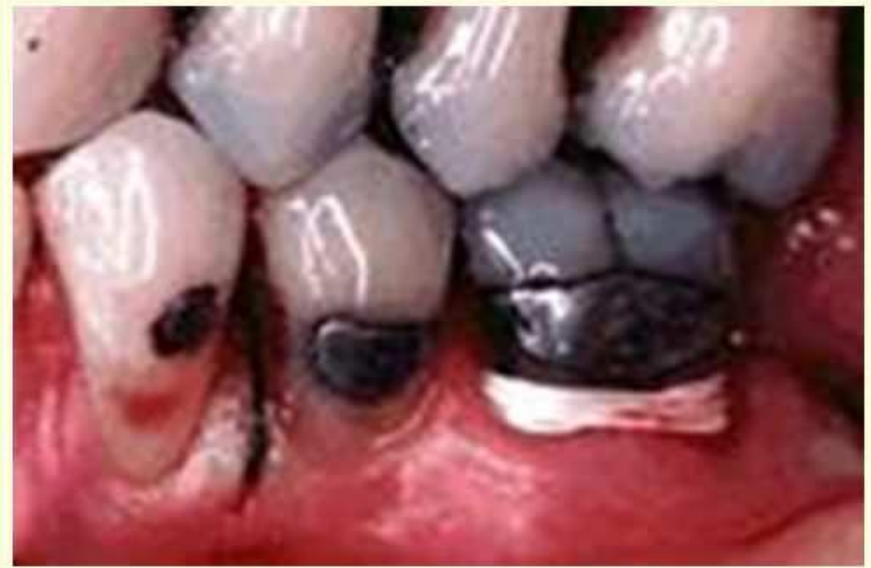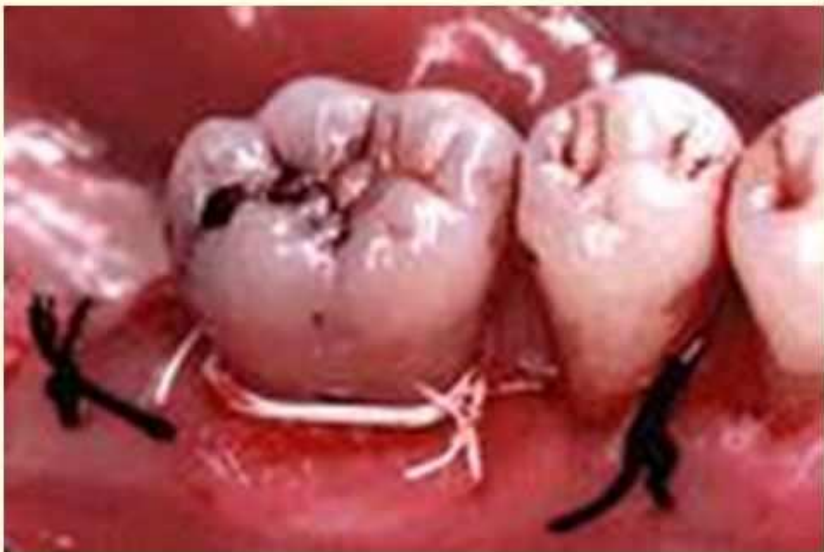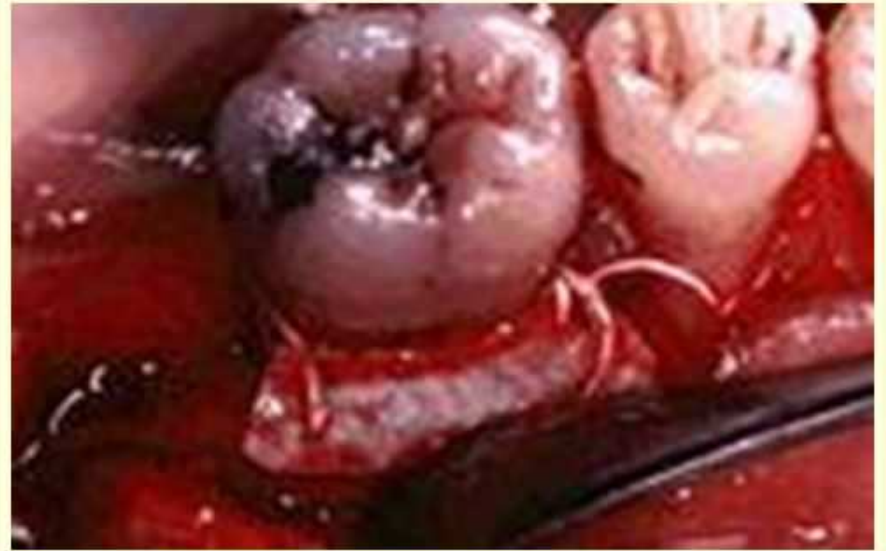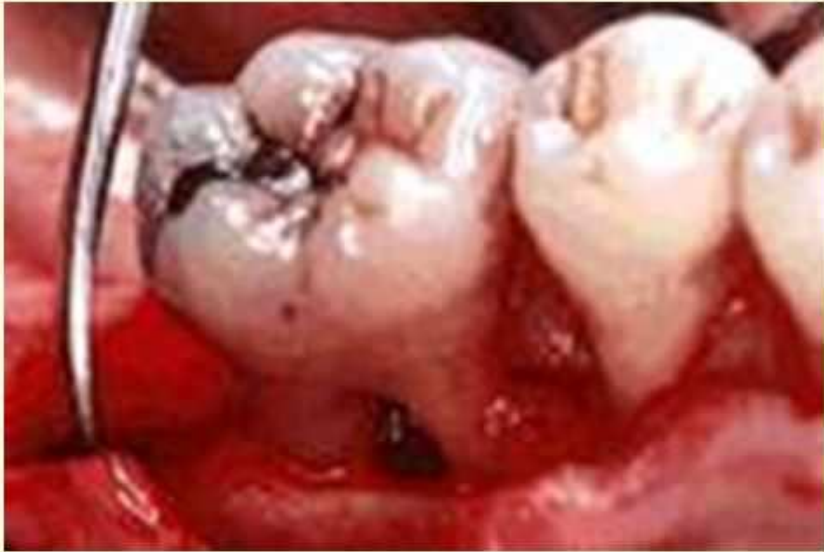Perawatan cacat tulang yang dalam pada akar distal mandibula dengan teknik regenerasi jaringan terarah








KOMBINASI CANGKOK TULANG DGN REGENERASI JAR. TERARAH


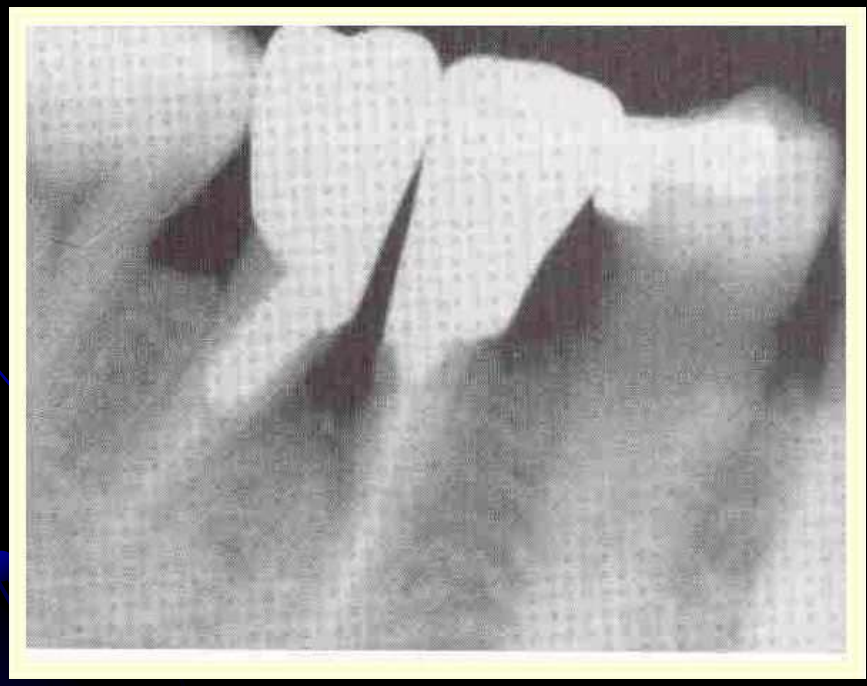
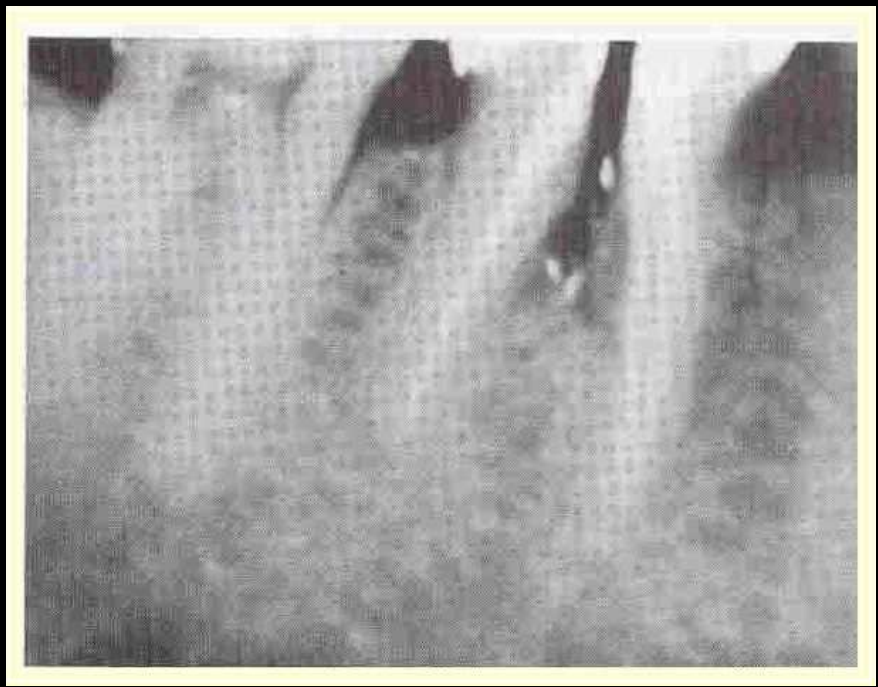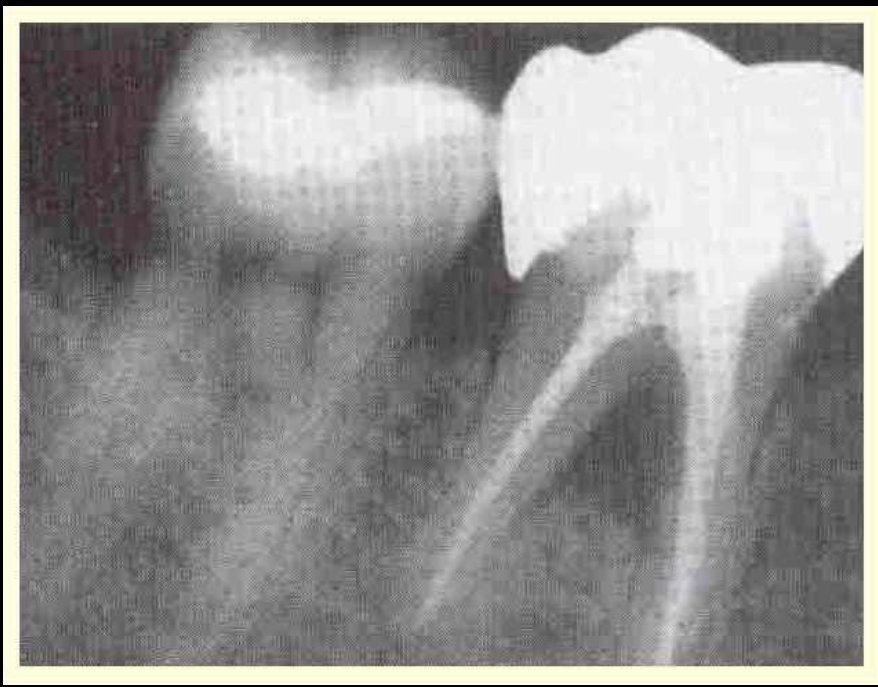
Kedua teknik dikombinasikan untuk mendapatkan hasil yg lebih memuaskan.

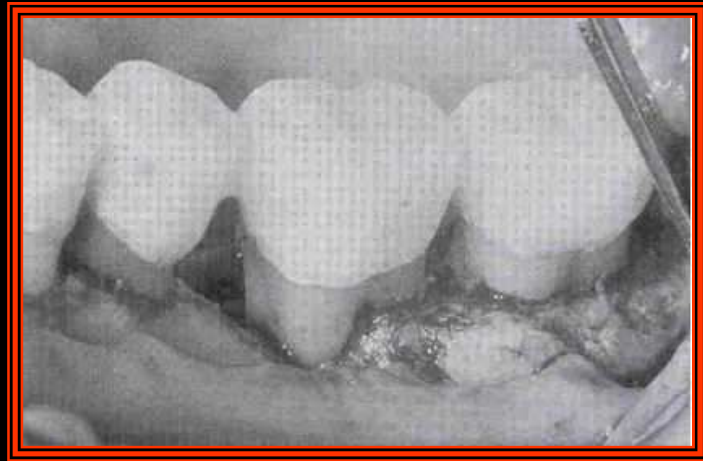
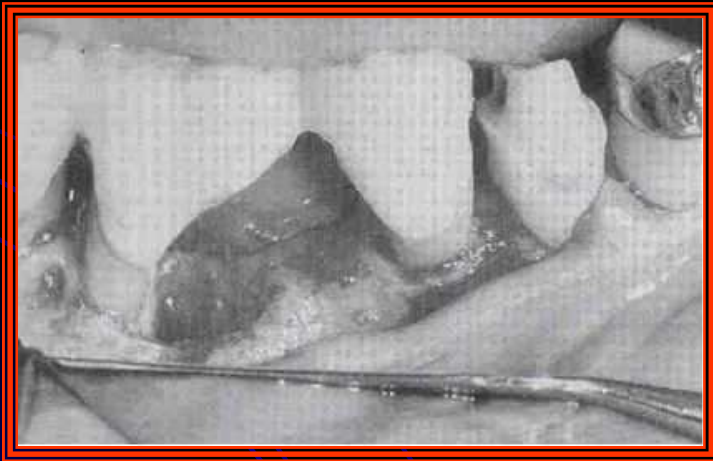
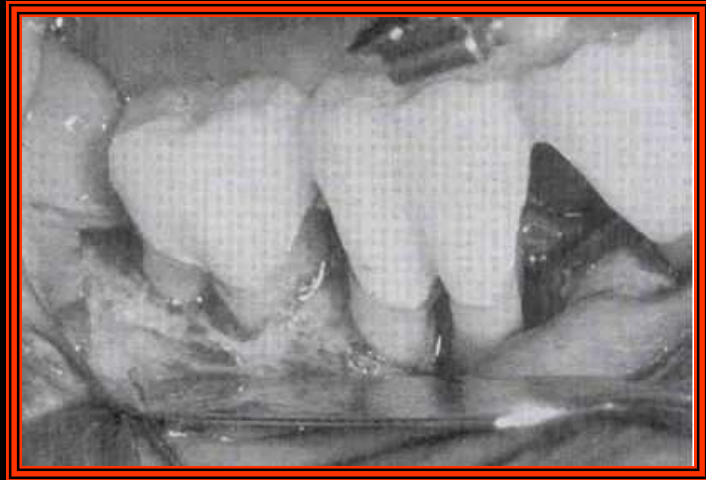
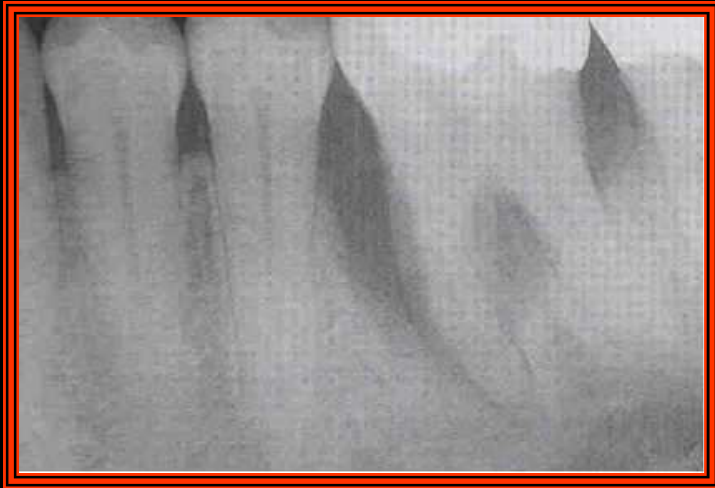


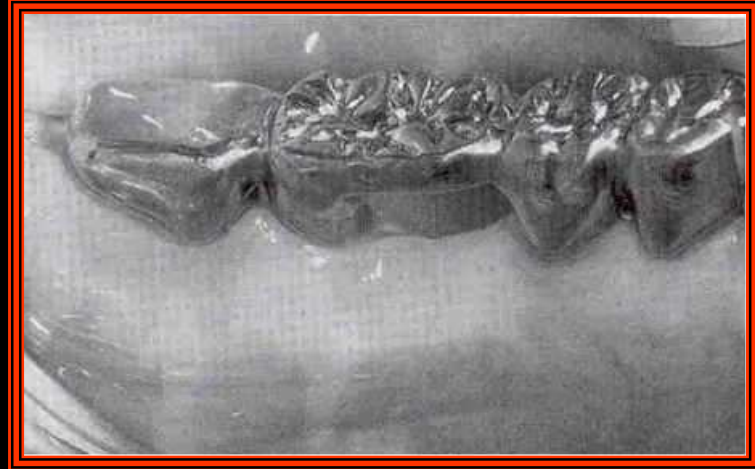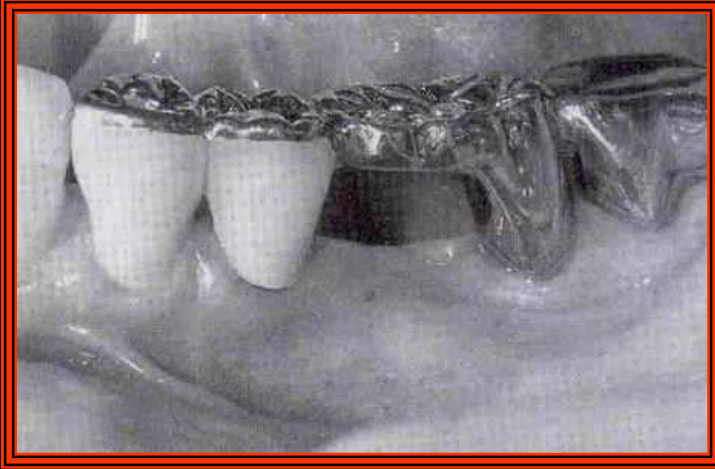PERAWATAN LESI FURKASI

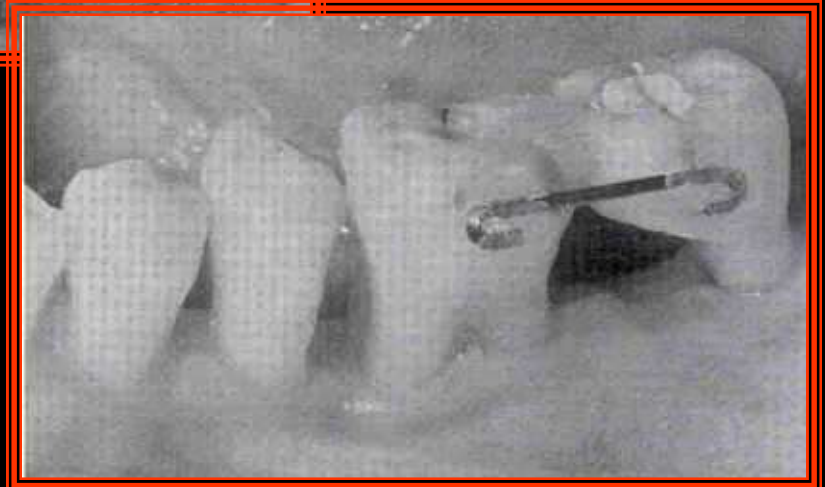
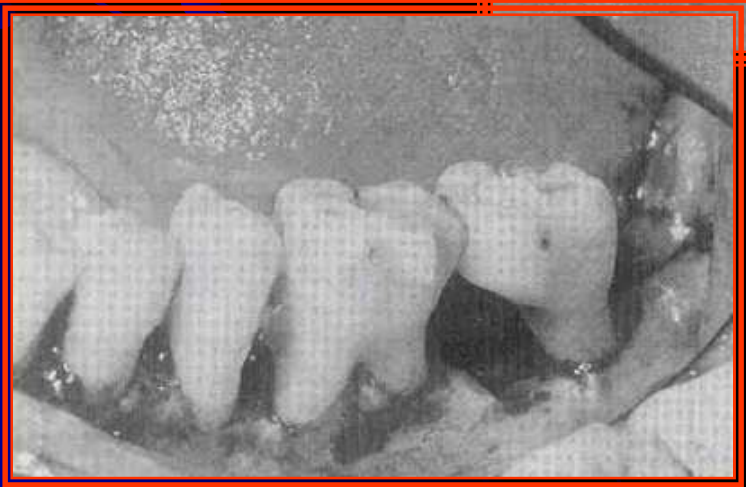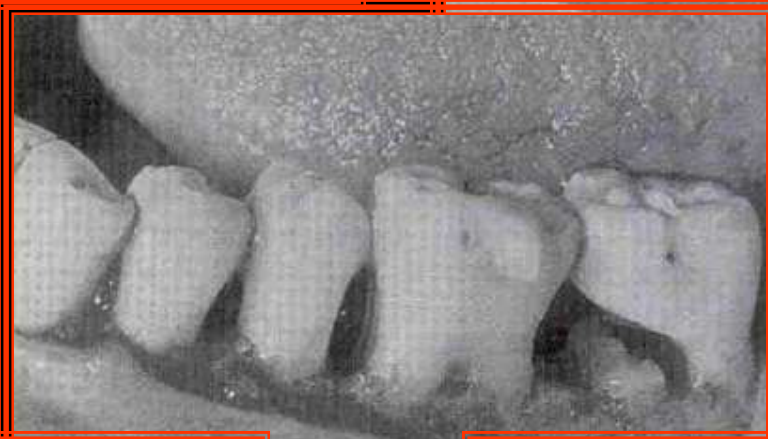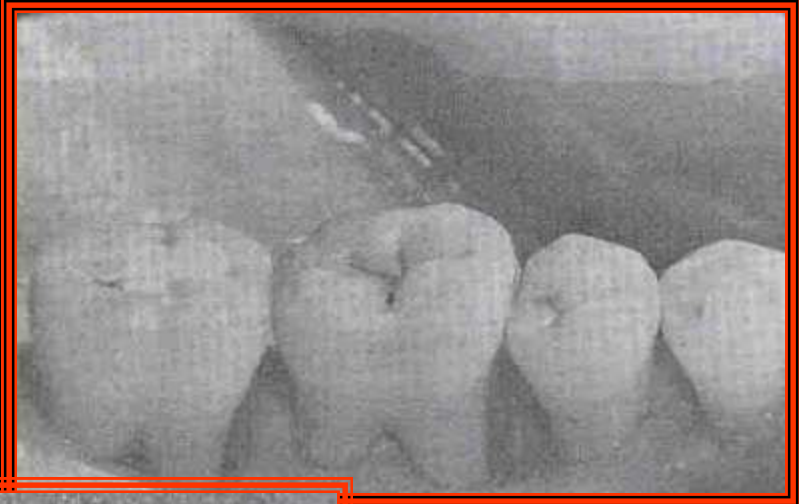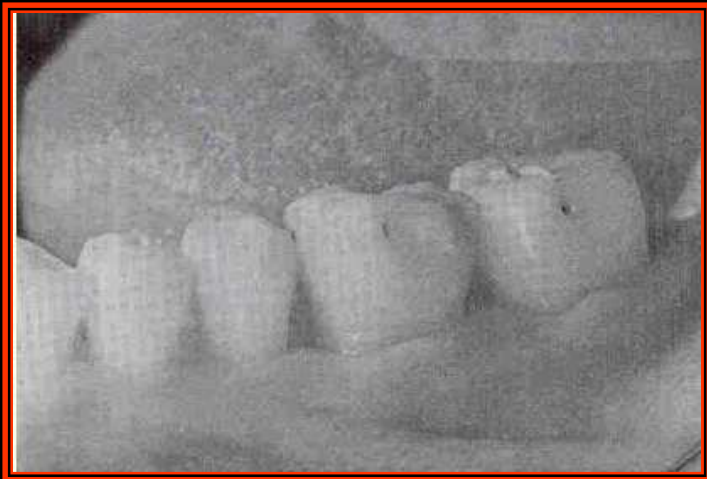
Tergantung pada derajat lesi furkasinya.

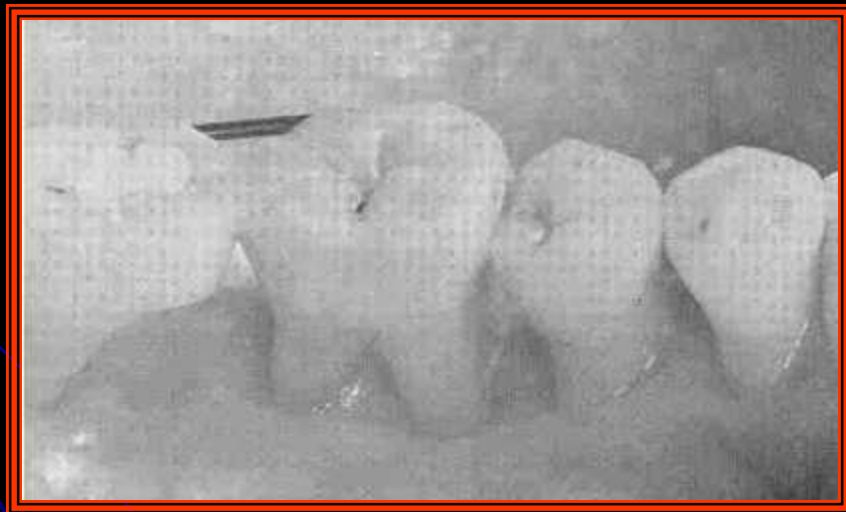
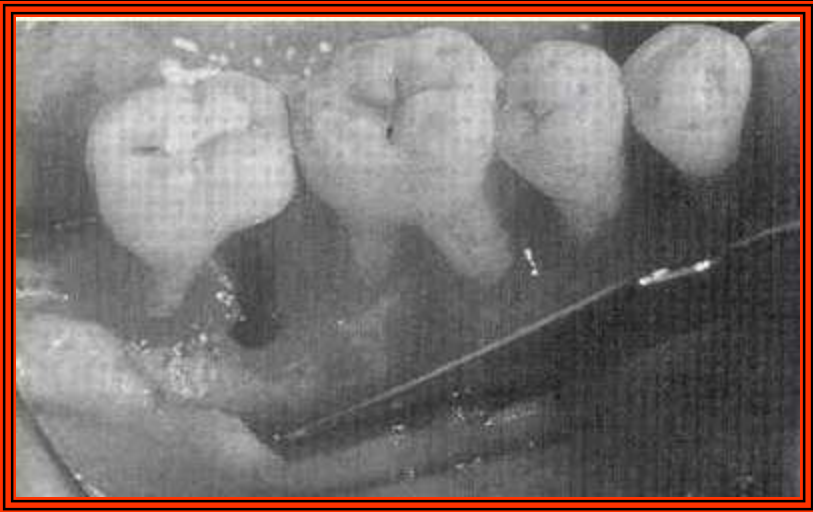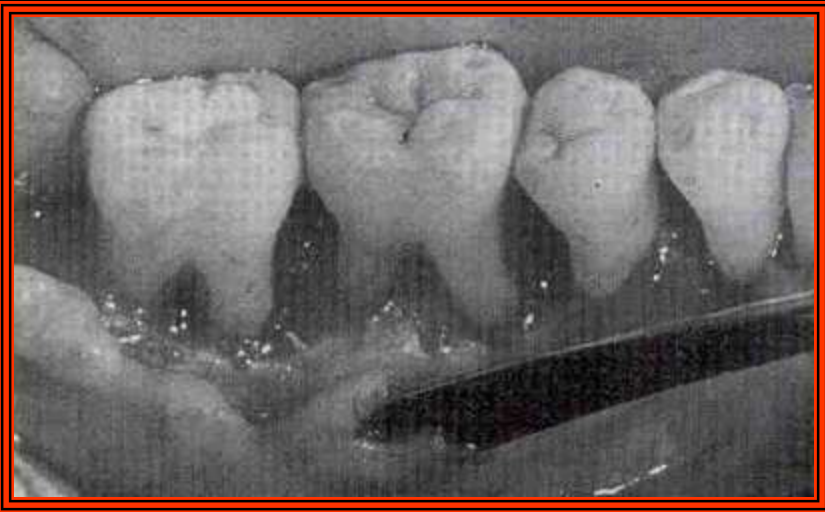Derajat	Perawatan
I	Perawatan inisial
II	Lesi ringan : Perawatan inisial Lesi lebih parah : Bedah flep, reseksi akar, hemiseksi, RJT
III dan IV	Furkasiplastik, reseksi akar, biseksi, hemiseksi



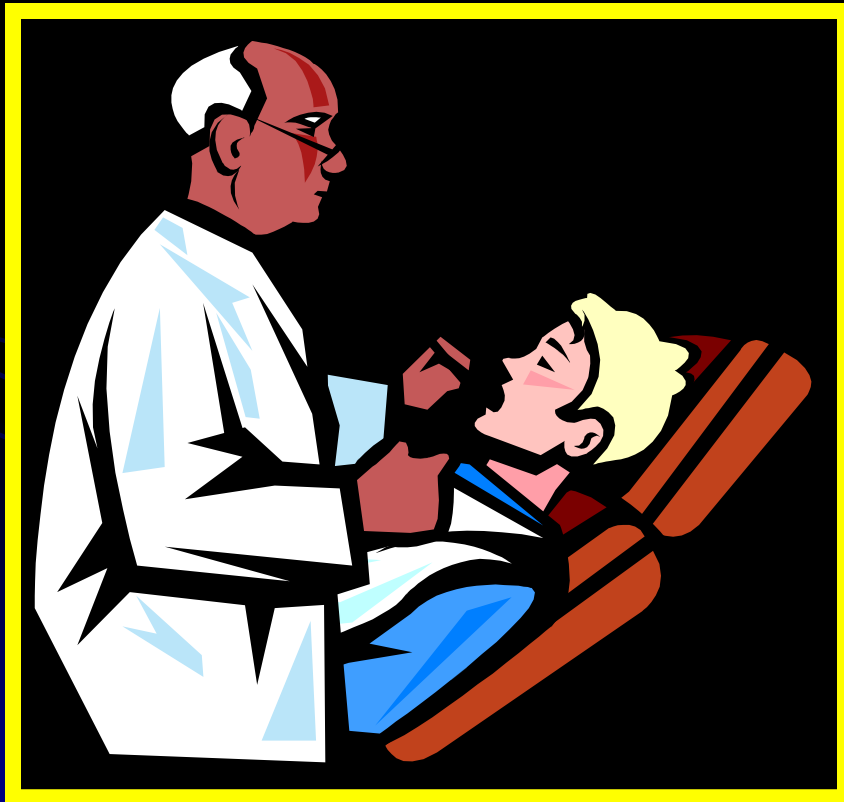







SEKIAN



**Selamat
belajar**